WORKSHOP ECHOGRAFIE

DAM CONGRES

10-06-2016

Termen

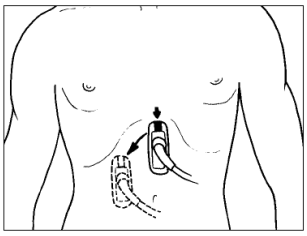

Sliding

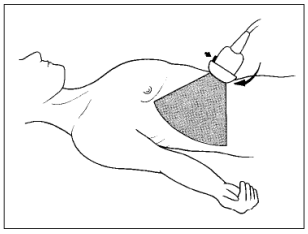

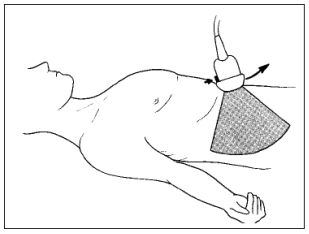

Rocking

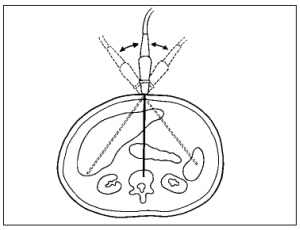

Tilting

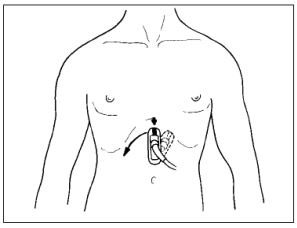

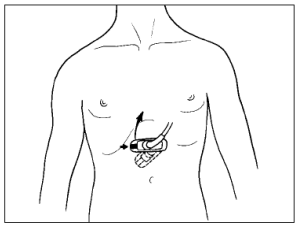

Roteren

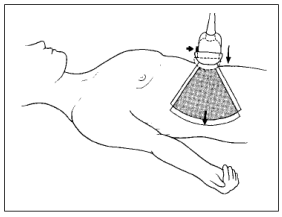

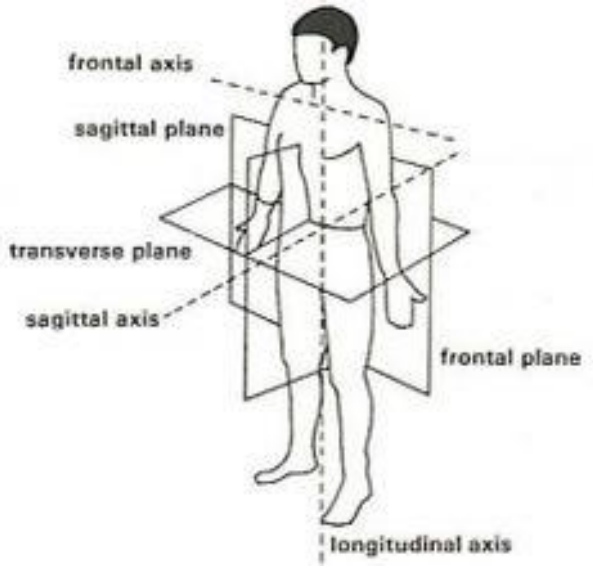
frontal axis
sagittal plane
transverse plane
sagittal axis
frontal plane
longitudinal axis

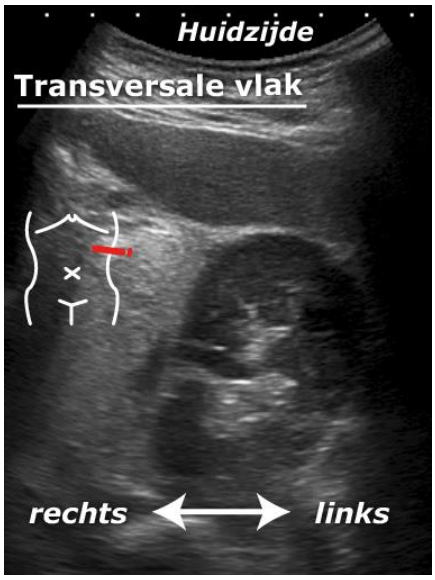
Huidzijde
Transversale vlak
rechts
links

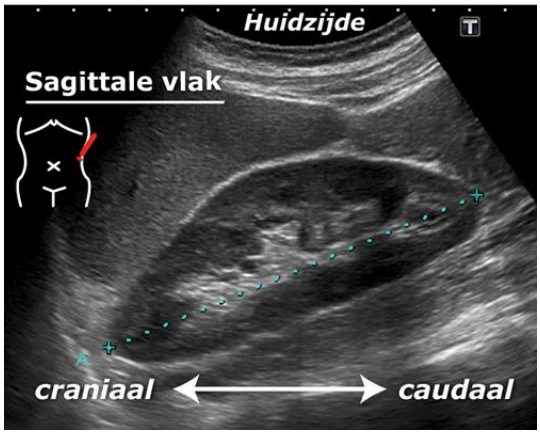
Huidzijde
Sagittale vlak
craniaal
caudaal

FAST: Focussed Assessment with Sonography for Trauma

Doel: Aantonen vrij vocht in thorax en buik

Vier posities:

1. Transducer in epigastrio in tranverse veld en naar caudaal getild.
2. Transducer in de rechter anterior axillair lijn.
3. Transducer in de linker posterior axillair lijn.
4. Transducer mediaan in de suprapubische regio in het sagitale veld, gericht naar caudaal.

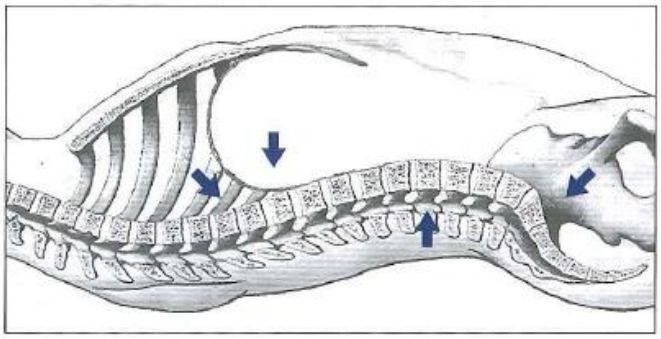

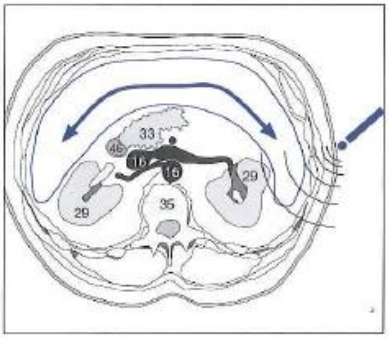

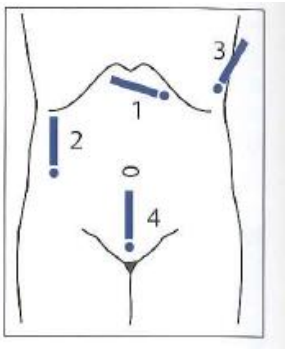

Positie 1: Transducer in epigastrio in tranverse veld en naar caudaal gericht.

Doel: evaluatie hart en pericard voor pericardeffussie

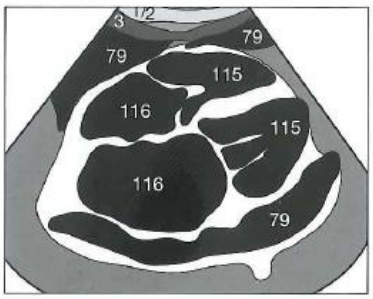

1. Positie transducer: Transducer in epigastrio in tranverse veld en naar caudaal getild.
2. Echobeeld
3.
   - 1 en 2: Huid en subcutaan vet
   - 79: Pericardeffussie
   - 115: Ventrikel
   - 116: Atrium

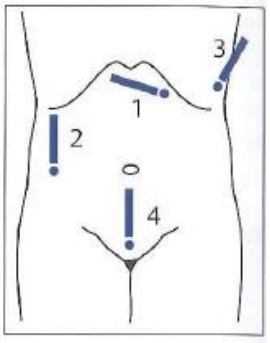

Positie 2: Transducer in de rechter anterior axillair lijn.

Doel: evaluatie hematothorax en vrij vocht in het abdomen (Morrisons Pouch)

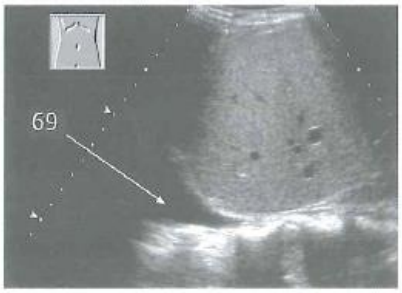

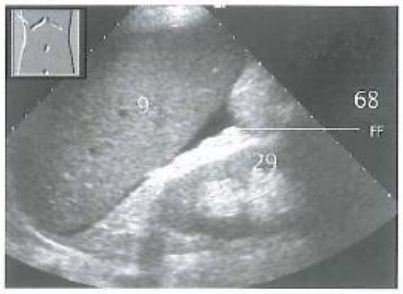

1. Positie transducer: Transducer in de rechter anterior axillair lijn.
2. Echobeeld
    - 69: Pleuravocht
3. Echobeeld
    - 9: Lobus caudatus
    - 29: Nierparenchym
    - 68: Vrij vocht

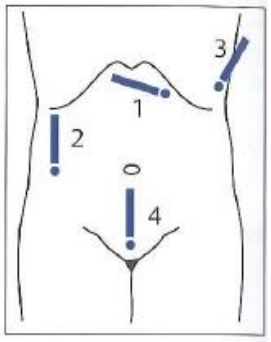

Positie 3: Transducer in de linker posterior axillair lijn.

Doel: evaluatie hematothorax links, miltruptuur, vrij vocht in spenorenale ruimte

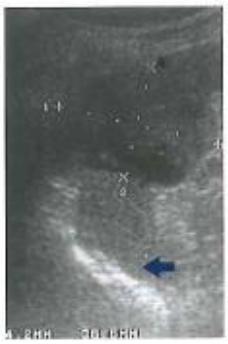
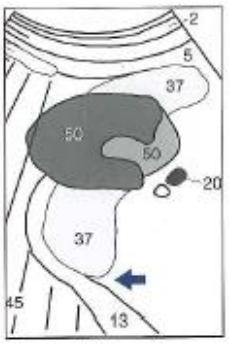

1. Positie transducer: Transducer in de linker posterior axillair lijn.

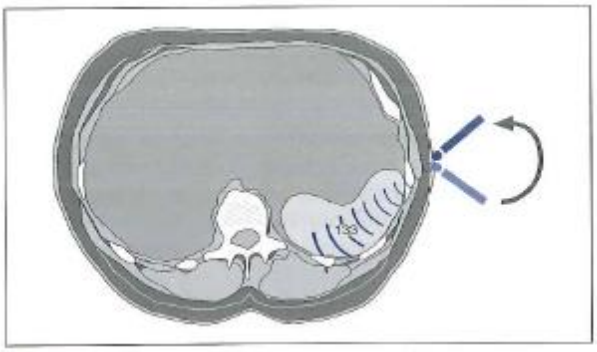
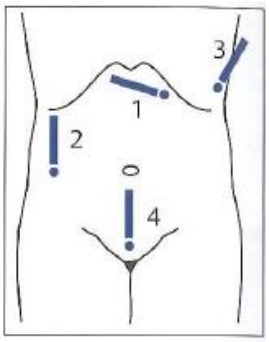

2. Echobeeld
    - Bloeding milt
3. Overzicht
    - 13: Diafragma
    - 37: Milt
    - 50: Hematoom (solide en vloeibaar)
4. Echobeeld
    - 29: Nierparenchym
    - 37: Milt
    - 68: Vrij vocht

Positie 4: Transducer mediaan in de suprapubische regio in het sagitale veld, gericht naar caudaal.

Doel: Evaluatie vocht in Douglas

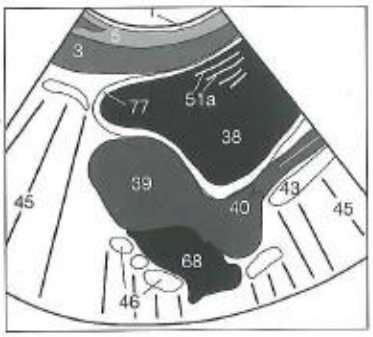

1. Positie transducer: Transducer mediaan in de suprapubische regio in het sagitale veld, gericht naar caudaal.
2. Echobeeld
3. Overzicht
    - 3: Rectus
    - 39: Uterus
    - 40: Cervix
    - 45: Slagschaduw
    - 51: Artefacten
    - 68: Vrij vocht
    - 77: Blaaswand

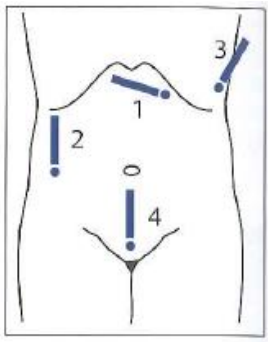

ECHO DVT

Doel: Vaststellen diep veneuze thrombose

Posities:

- Vena femoralis
- Vene traject
- Vena poplitia

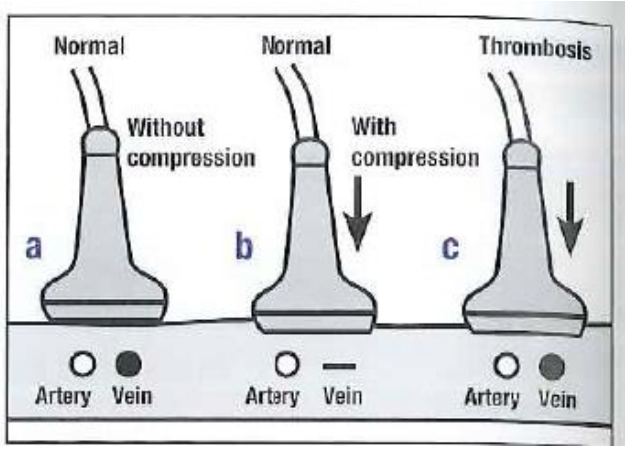

Werkwijze:

- Identificeren vene en arterie
- Compressie van de vene met de echokop
- Zo nodig gebruik doppler

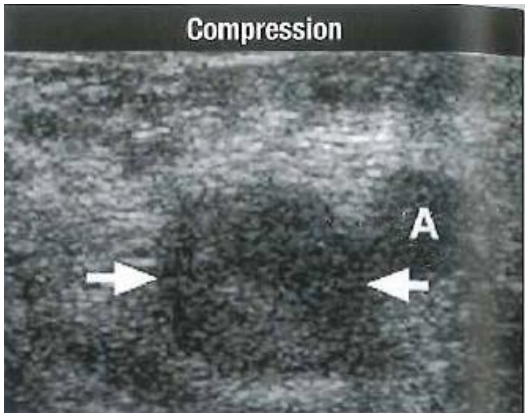

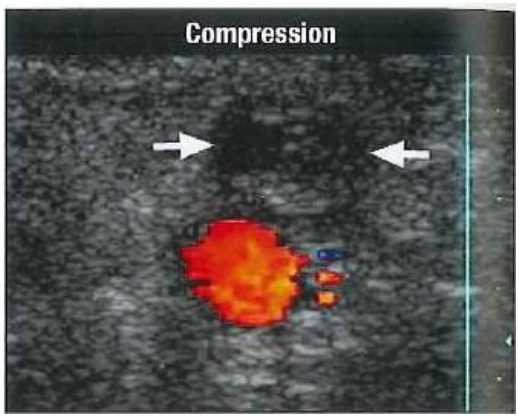

Echo:

1. Niet comprimeerbare vene met thrombus
2. Afwezige signalen doppler in de vene

Echo nieren en blaas

Doel: vaststellen postrenale oorzaak nierfunctiestoornissen

Onderdelen:

- Rechternier
- Linkernier
- Blaas

Rechternier

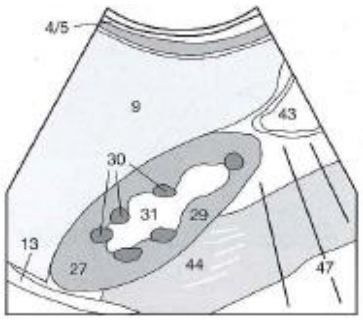

1. Positie transducer: Rechternier: longitudinale veld in de axillair lijn (let op inademing)
2. Echobeeld
3.
    - 27: Nier
    - 31: Nierbekken
    - 30: Medulla

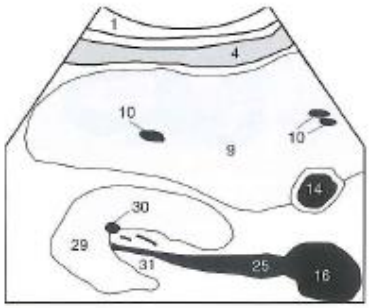

4. Positie transducer: Rechternier: transverse veld (let op inademing)
5. Echobeeld
6.
    - 9: Lever
    - 27: Nier
    - 31: Bekken
    - 30: Medulla

7. Alternatieve positie: parallel aan de intercostaalruimte

Linkernier

Positie: Transverse en longitudinale veld met patiënt in rugligging of in rechterzij ligging (let op inademing)

Gedilateerd pyelum

Fig. 52.1 a

Fig. 52.2 a

Fig. 52.3 a

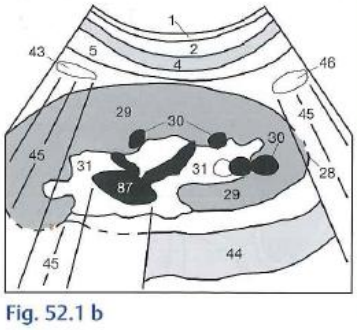

Fig. 52.1 b

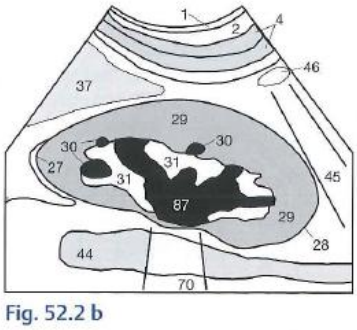

Fig. 52.2 b

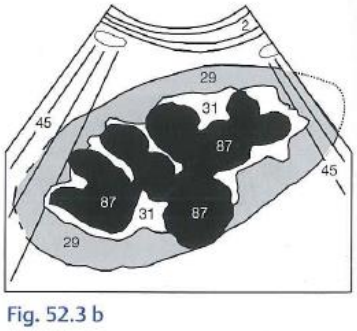

Fig. 52.3 b

Echo blaas

Doel: blaasretentie of residu na mictie

Positie: Suprapubisch transverse en sagitale veld.

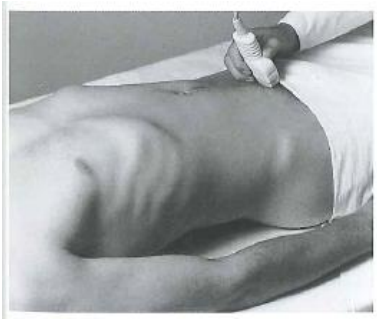
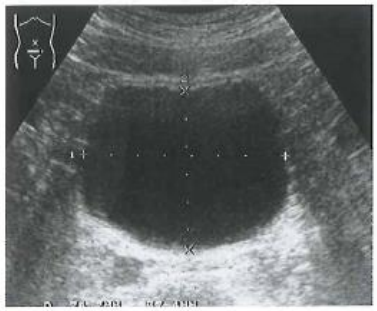
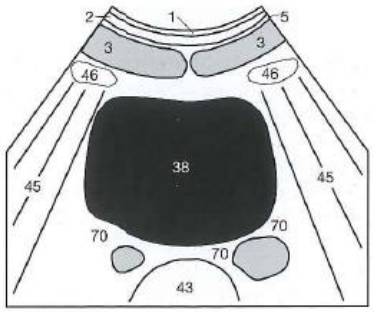

1. Positie transverse veld
2. Echobeeld
3.
    - 38: blaas
    - 43: colon
    - 46: dunne darm

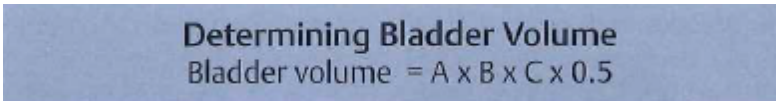

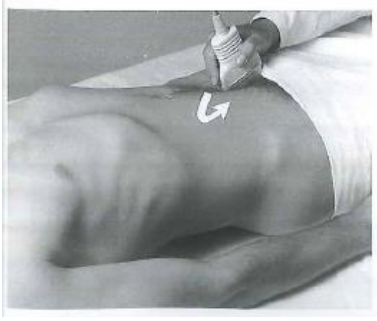
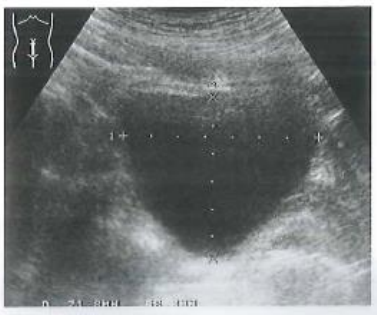

4. Positie sagitale veld
5. Echobeeld
6.
    - 38: blaas
    - 42: uterus
    - 43: colon
    - 46: dunne darm

Vena cava

Doel: Beoordelen vena cava op overvulling

Positie: Epigastrio rechts van de mediaanlijn in longitudinale vlak

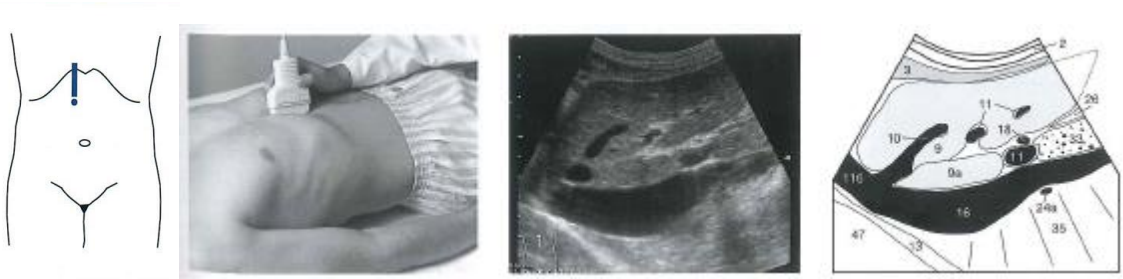

1. Positie transducer
2. Positie transducer
3. Echobeeld
4.
    - 16: vena cava
    - 116: rechter atrium

Checklist for Right Heart Failure

- IVC dilated > 20 mm or
  > 25 mm in young athletes
- Dilated hepatic veins > 6 mm
  in the periphery of the liver
- IVC does not collapse on forced inspiration
- Possible pleural effusion,
  often initially unilateral on the right

Werkwijze vena cava collaps:
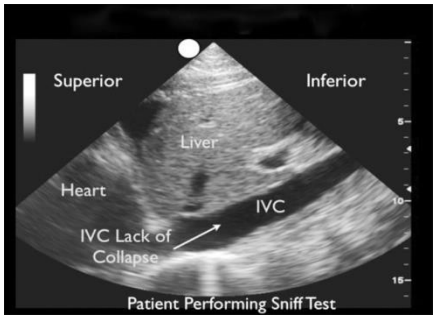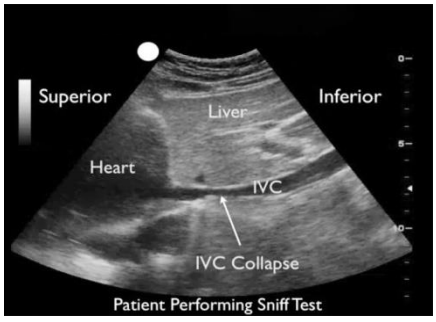
1. Patiënt moet zo diep mogelijk door neus inademen (“sniff-test)
2. Echografist moet vena cava in beeld houden
3. Cava moet collaberen tot 1/3 van initiele diameter